

Needle knife recanalization of a complete post-transplant bile duct stricture

Benign biliary strictures are established complications after liver transplantation, commonly occurring at the duct-to-duct anastomosis [1]. Severe anastomotic strictures may not be amendable to the gold standard endoscopic therapy.

A 65-year-old-man with a history of alcoholic cirrhosis who had undergone liver transplantation 1 year previously was referred for endoscopic retrograde cholan-

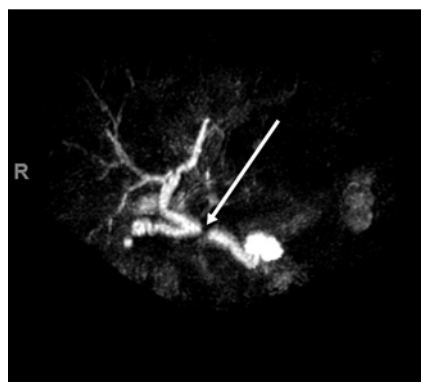
giography (ERCP) after outpatient laboratory evaluation revealed signs of cholestasis and magnetic resonance cholangiopancreatography (MRCP) revealed a complete anastomotic stricture (►Fig.1). ERCP was performed and confirmed these findings; in addition, difficulty was encountered while attempting to traverse the stricture with a 0.025-inch guidewire (►Fig.2a). Cholangioscopy was performed, but manipulation with cholangioscopic biopsy forceps was unsuccessful. The guidewire was downsized to a 0.018-inch wire and the stricture was traversed; however, attempts to dilate the anastomotic stricture with various dilating catheters were unsuccessful. A needle knife was then loaded over the guidewire, electrocautery was applied, and the stricture was recanalized successfully (►Video 1). After this maneuver, there was no evidence of contrast extravasation, which would have suggested bile duct injury (►Fig.2b). A follow-up ERCP 4 weeks later revealed improvement in the anastomotic stricture and a 0.035-inch guidewire was easily passed beyond

the stricture (►Fig.2sc). This allowed for routine biliary balloon dilation to 6 mm and placement of a 12-cm 11.5-Fr stent. Bile duct recanalization has previously been achieved using a combined percutaneous and endoscopic approach [2]. Gupta et al. used a specific needle knife for puncture that allowed a wire to pass through the needle and stricture [3]. Recently, a standard needle knife has been used to cut and puncture these strictures [4]. In our case, cholangioscopic guidance was first used to pass a wire, which allowed for a controlled cut using the loaded needle knife. This technique may be used as a minimally invasive alternative to surgical repair in short anastomotic strictures.

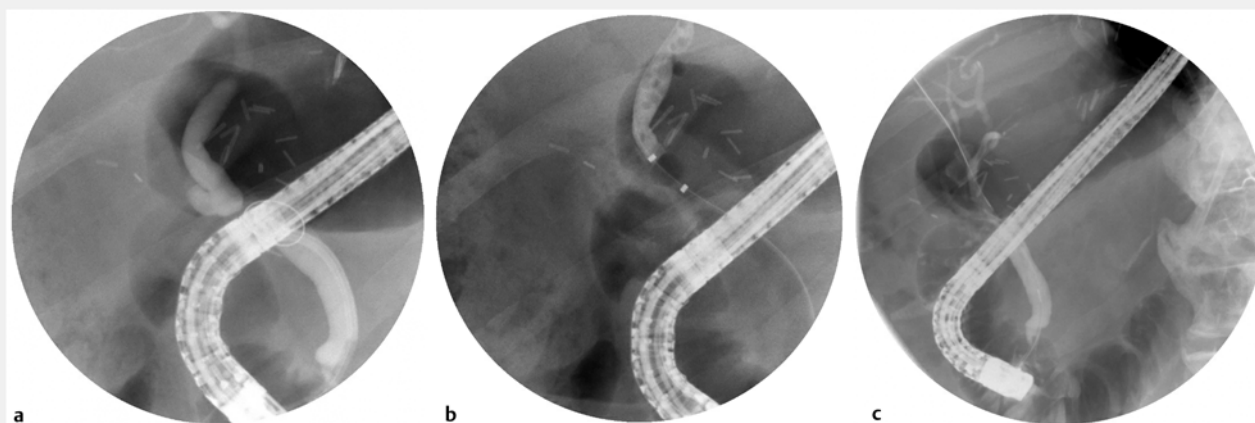
Endoscopy_UCTN_Code_TTT_1AR_2AG

Competing interests

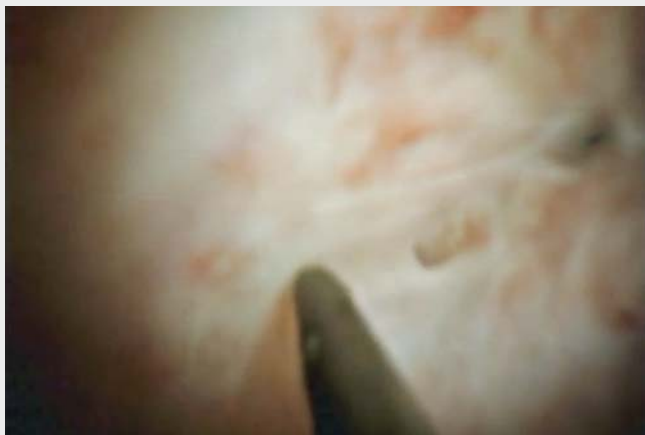The authors declare that they have no conflict of interest.



► Fig.1 Magnetic resonance cholangiopancreatography (MRCP) image showing a severe, short localized stricture.



► Fig.2 Cholangiogram images showing: **a** a wire coiling at the level of the stricture prior to the needle knife procedure; **b** no evidence of contrast extravasation after needle knife electrocautery of the complete anastomotic stricture; **c** the appearance at follow-up 4 weeks after the procedure.



Video 1 Needle knife recanalization of a complete bile duct stricture following liver transplantation.

- [4] Martins FP, De Paulo GA, Macedo EP et al. Endoscopic biliary recanalization with a needle-knife in post liver-transplant complete anastomotic stricture. *Endoscopy* 2012; 44: 304–305

Bibliography

Endoscopy 2022; 54: E28–E29

DOI 10.1055/a-1353-4734

ISSN 0013-726X

published online 19.2.2021

© 2021. Thieme. All rights reserved.

Georg Thieme Verlag KG, Rüdigerstraße 14, 70469 Stuttgart, Germany

ENDOSCOPY E-VIDEOS

<https://eref.thieme.de/e-videos>



Endoscopy E-Videos is a free access online section, reporting on interesting cases and new techniques in gastroenterological endoscopy. All papers include a high quality video and all contributions are freely accessible online.

This section has its own submission website at <https://mc.manuscriptcentral.com/e-videos>

The authors

Ramzi Mulki **Mohamed Abdelfatah**

Department of Gastroenterology and Hepatology, The University of Alabama at Birmingham School of Medicine, Birmingham, Alabama, USA

Corresponding author

Ramzi Mulki, MD

The University of Alabama at Birmingham School of Medicine – Gastroenterology & Hepatology, BDB 366, 1720 2nd Ave, Birmingham, Alabama 35294-3412, USA
ramzi.mulki@gmail.com

References

- [1] Safdar K, Atiq M, Stewart C et al. Biliary tract complications after liver transplantation. *Expert Rev Gastroenterol Hepatol* 2009; 3: 183–195
- [2] Bukhari MA, Haito-Chavez Y, Ngamruengphong S et al. Rendezvous biliary recanalization of complete biliary obstruction with direct peroral and percutaneous transhepatic cholangioscopy. *Gastroenterology* 2018; 154: 23–25
- [3] Gupta K, Aparicio D, Freeman ML et al. Endoscopic biliary recanalization by using a needle catheter in patients with complete ligation or stricture of the bile duct: safety and feasibility of a novel technique (with videos). *Gastrointest Endosc* 2011; 74: 423–428