

DEN Video Article

Moving scope technique for guidewire insertion during endoscopic ultrasound-guided hepaticogastrostomy

Saori Ueno, Takeshi Ogura  and Kazuhide Higuchi2nd Department of Internal Medicine, Osaka Medical College, Osaka, Japan

BRIEF EXPLANATION

ENDOSCOPIC ULTRASOUND-GUIDED HEPATICO-GASTROSTOMY (EUS-HGS) has emerged as an alternative method of biliary drainage for not only malignant biliary obstruction, but also benign biliary disease.^{1–3} However, guidewire manipulation is one of the most challenging steps during EUS-HGS.⁴ If the guidewire is advanced into the periphery of the bile duct, the guidewire might become sheared with the needle. Liver impaction technique might be useful in this situation. However, the angle between the bile duct and the needle is almost 90°, which could render guidewire insertion into hepatic hilum impossible. We herein describe a novel technique to achieve correct alignment between the bile duct and the needle.

A 68-year-old man was admitted with frequent cholangitis due to hepaticojejunostomy stricture. He had

undergone pancreaticoduodenectomy due to bile duct cancer 2 years previously. We initially attempted EUS-guided biliary drainage because the enteroscopic approach failed. A UCT260 echoendoscope (Olympus Optical, Tokyo, Japan) was advanced into the stomach, and the intrahepatic bile duct was identified. The intrahepatic bile duct was punctured using a 19G Sono Tip Pro Control needle (Medi-Globe GmbH, Rohrdorf, Germany), contrast medium was injected, then a guidewire was inserted. However, the guidewire was advanced into the periphery of the bile duct (Fig. 1a). Although liver impaction was attempted,⁵ the guidewire could not be advanced into the hepatic hilum. We then pushed the echoendoscope downwards to align the bile duct and the needle (Fig. 1b,c), and the guidewire was inserted into the hepatic hilum (Fig. 2a). The intrahepatic bile duct and stomach wall were dilated using a 4-mm, balloon catheter, then a self-expandable Niti-S Biliary Cover

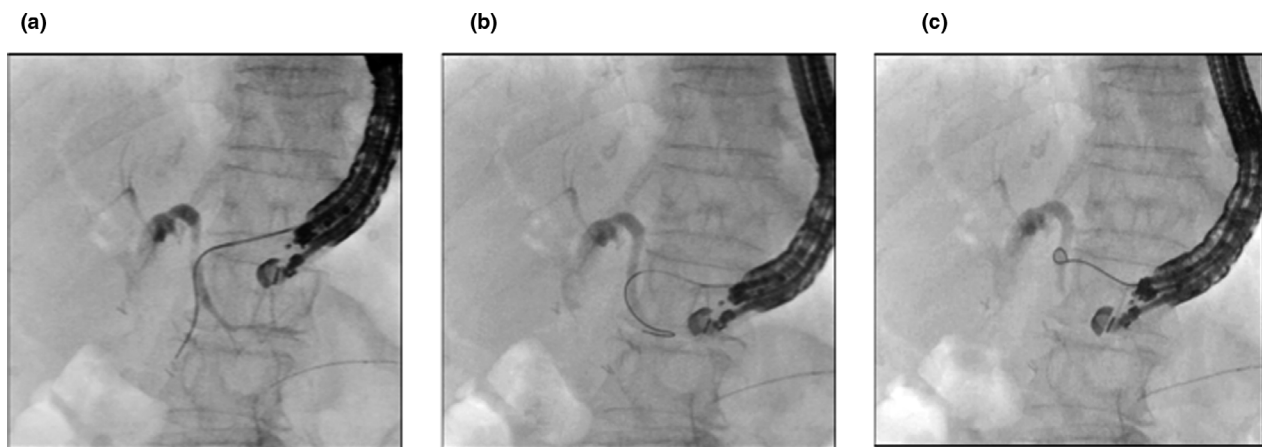


Figure 1 (a) Guidewire is advanced into bile duct periphery. (b) Echoendoscope is pushed to align bile duct and needle. (c) Guidewire is gently pulled.

Corresponding: Takeshi Ogura, 2nd Department of Internal Medicine, Osaka Medical College, 2-7 Daigakuchou, Takatsukishi, Osaka 569-8686, Japan. Email: oguratakeshi0411@yahoo.co.jp

Received 4 February 2021; accepted 14 April 2021.

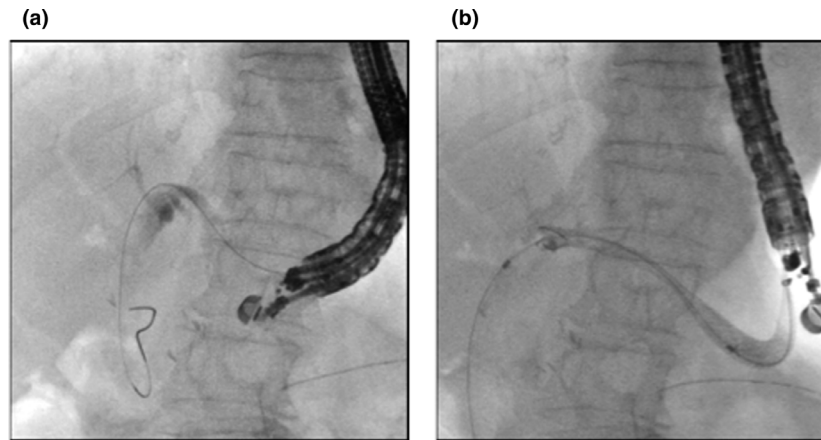


Figure 2 (a) Guidewire is advanced into hepatic hilum. (b) Endoscopic ultrasound-guided hepaticogastrostomy proceeds using covered self-expandable metal stent.

Stent (Fig. 2b) was deployed (TaeWoong Medical, Seoul, South Korea) (Video S1). Although our technique should be studied in a large patient cohort, it might nevertheless help to improve the technical success rate of guidewire insertion during EUS-HGS.

Authors declare no conflict of interest for this article.

REFERENCES

- 1 Guo J, Giovannini M, Sahai AV *et al.* A multi-institution consensus on how to perform EUS-guided biliary drainage for malignant biliary obstruction. *Endosc Ultrasound* 2018; **7**: 356–65.
- 2 Boulay BR, Lo SK. Endoscopic ultrasound-guided biliary drainage. *Gastrointest Endosc Clin N Am* 2018; **28**: 171–85.
- 3 Baars JE, Kaffes AJ, Saxena P. EUS-guided biliary drainage: A comprehensive review of the literature. *Endosc Ultrasound* 2018; **7**: 4–9.
- 4 Vila JJ, Pérez-Miranda M, Vazquez-Sequeiros E *et al.* Initial experience with EUS-guided cholangiopancreatography for

biliary and pancreatic duct drainage: A Spanish national survey. *Gastrointest Endosc* 2012; **76**: 1133–41.

- 5 Ogura T, Masuda D, Takeuchi T *et al.* Liver impaction technique to prevent shearing of the guidewire during endoscopic ultrasound-guided hepaticogastrostomy. *Endoscopy* 2015; **47**: E583–4.

SUPPORTING INFORMATION

ADDITIONAL SUPPORTING INFORMATION may be found in the online version of this article at the publisher's web site.

Video S1 Guidewire is advanced into bile duct periphery. Liver impaction technique was attempted, but failed. Echoendoscope is pushed to fit alignment. Guidewire is then advanced into hepatic hilum. Intrahepatic bile duct and stomach wall are dilated using balloon catheter and covered self-expandable metal stent is deployed from bile duct to stomach.